Medical Endoscopy Report

Patient Information

Patient Name: ABDUL RASAK

Patient ID: ABDUL RASAK_489493_RP241106_122041

Report Date: 2026-04-13 18:09:46

Endoscopy Images

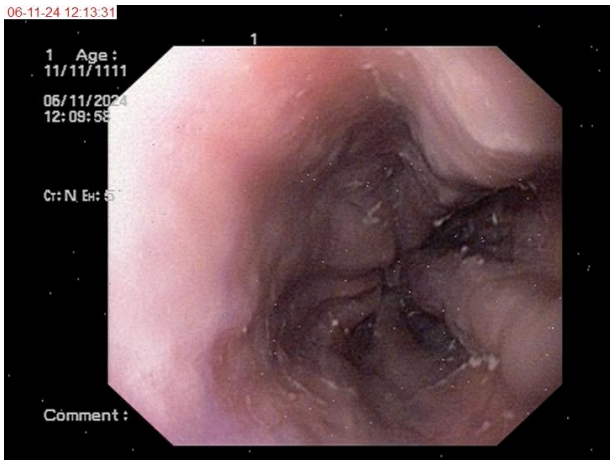

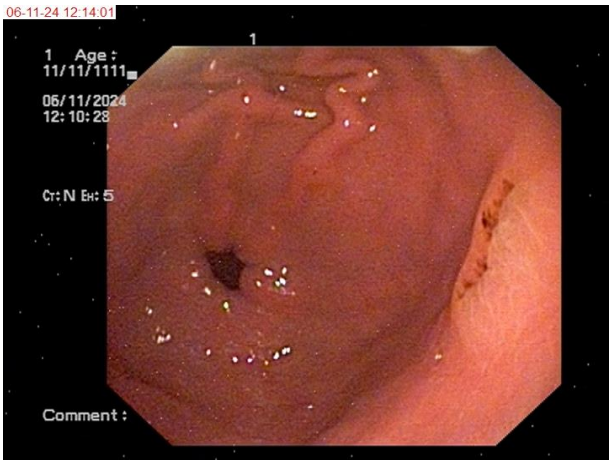

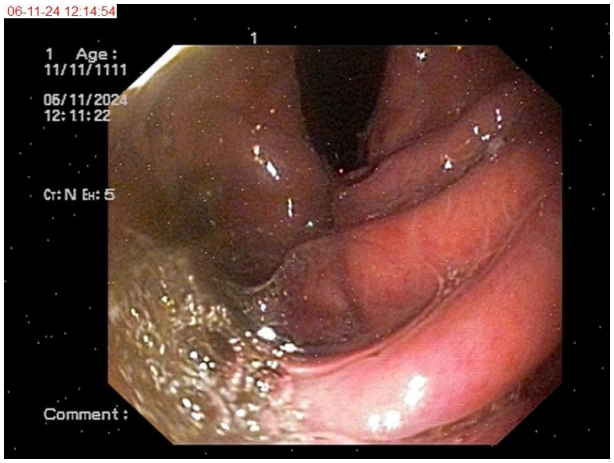

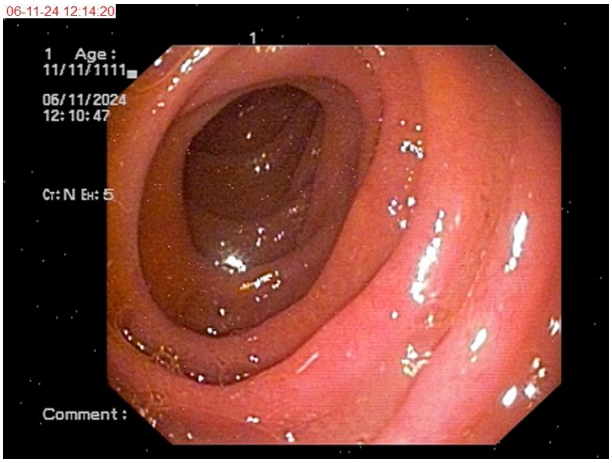

Findings

Indication:	CLD-UGIB
Scope Passed Upto:	D2
Premedication:	Lignocaine spray
Esophagus:	Normal
Ge Junction:	Lax at 38cm

Stomach:	
Fundus:	Normal
Body:	Edematous mucosa noted
Antrum:	Erythematous mucosa noted
Pylorus:	Normal
Duodenum:	D1: Normal | D2: Normal
Rut:	Not taken
Biopsy:	Not taken
Impression:	LAX GE JUNCTION HIATUS HERNIA ANTRAL ULCERS- FORREST CLASS III BODY POLYP REMOVED WITH TPS PLAN : SVE